

***Yersinia pseudotuberculosis* Septicemia in a Beaver from Washington State**

Author(s): Joseph K. Gaydos, Erin Zabek, and Stephen Raverty

Source: Journal of Wildlife Diseases, 45(4):1182-1186.

Published By: Wildlife Disease Association

<https://doi.org/10.7589/0090-3558-45.4.1182>

URL: <http://www.bioone.org/doi/full/10.7589/0090-3558-45.4.1182>

BioOne (www.bioone.org) is a nonprofit, online aggregation of core research in the biological, ecological, and environmental sciences. BioOne provides a sustainable online platform for over 170 journals and books published by nonprofit societies, associations, museums, institutions, and presses.

Your use of this PDF, the BioOne Web site, and all posted and associated content indicates your acceptance of BioOne's Terms of Use, available at www.bioone.org/page/terms_of_use.

Usage of BioOne content is strictly limited to personal, educational, and non-commercial use. Commercial inquiries or rights and permissions requests should be directed to the individual publisher as copyright holder.

***Yersinia pseudotuberculosis* Septicemia in a Beaver from Washington State**

Joseph K. Gaydos,^{1,3} Erin Zabek,² and Stephen Raverty² ¹Wildlife Health Center—Orcas Island Office, University of California, Davis, School of Veterinary Medicine, 942 Deer Harbor Road, Eastsound, Washington 98245, USA; ²Animal Health Centre, British Columbia Ministry of Agriculture and Food, 1767 Angus Campbell Road, Abbotsford, British Columbia V3G 2M3, Canada; ³Corresponding author: (email: jkgaydos@ucdavis.edu)

ABSTRACT: An emaciated, free-ranging, subadult, male beaver (*Castor canadensis*) was found dead and was necropsied. Microscopically, the beaver had acute necrotizing hepatitis and splenitis with florid lobulated colonies of extracellular coccobacilli. Intravascular septic emboli were identified in lung, small intestine, and kidney, and discrete ulcers with scattered superficial extracellular accumulation of coccobacilli were noted on tail margins and plantar surfaces of the hind feet. *Yersinia pseudotuberculosis* was cultured on Columbia blood and MacConkey agar and identified by API 20E. Based on the pathology and acute mortality described in this case, as well as historical reports of *Y. pseudotuberculosis* related mortality in other beavers, this species could serve as a public health sentinel for localized occurrences of this bacterium.

Key words: Beaver, *Castor canadensis*, *Yersinia pseudotuberculosis*, yersiniosis.

The bacterium *Yersinia pseudotuberculosis* is a gram-negative, facultative anaerobe that causes disease in wildlife (Hubbert, 1972), domestic animals (Wallner-Pendleton and Cooper, 1983), and humans (Sato and Komagane, 1991). It was once thought that *Y. pseudotuberculosis* evolved from *Yersinia pestis* in Europe during a plague pandemic; however, more recent data suggest the opposite: that *Y. pestis* is a uniform clone of *Y. pseudotuberculosis* that arose shortly before the first known pandemics of plague (Achtman et al., 1999). *Yersinia pseudotuberculosis* is considered to be widely distributed geographically (Gasper and Watson, 2001); however, little work has been done to identify wildlife that could serve as public health sentinels for localized occurrences of this bacterium. Postmortem

necropsy results from this case, anecdotal information surrounding the case, and other reports of *Y. pseudotuberculosis*-associated mortality in beavers (*Castor canadensis*) suggest that beavers could be wildlife public health sentinels for localized occurrences of *Y. pseudotuberculosis*.

On 13 March 2007, private citizens found a dead beaver near a freshwater pond on San Juan Island (San Juan County, Washington State, USA; 48°35'N, 122°53'W) and took it to a local wildlife rehabilitation center. It was frozen until a necropsy could be performed on 18 April 2007. The 15-kg, male beaver was identified as a subadult and was estimated to be 2 yr old, based on weight, skull morphology, and histologic evidence of spermatogenesis (Larson, 1967). The carcass was in fair postmortem and poor nutritional condition. The distal and lateral margins of the tail were eroded and multiple 0.25- to 0.5-cm, circular ulcers were present on the plantar surface of both hind feet. Throughout the liver and spleen, there was focally disseminated parenchymal necrosis, characterized by white to yellow punctate foci occasionally bound by a thin margin of hemorrhage, and randomly, within the lungs, there were multifocal petechiae and ecchymoses. Based on gross examination, a generalized septicemia, possibly due to tularemia, was suspected.

Tissues were fixed in buffered 10% formalin, embedded in paraffin, sectioned at 5 µm, and stained with hematoxylin and eosin. Histopathology revealed acute, marked, necrotizing multifocal to coalescing hepatitis and splenitis with florid, lobulated colonies of extracellular cocco-

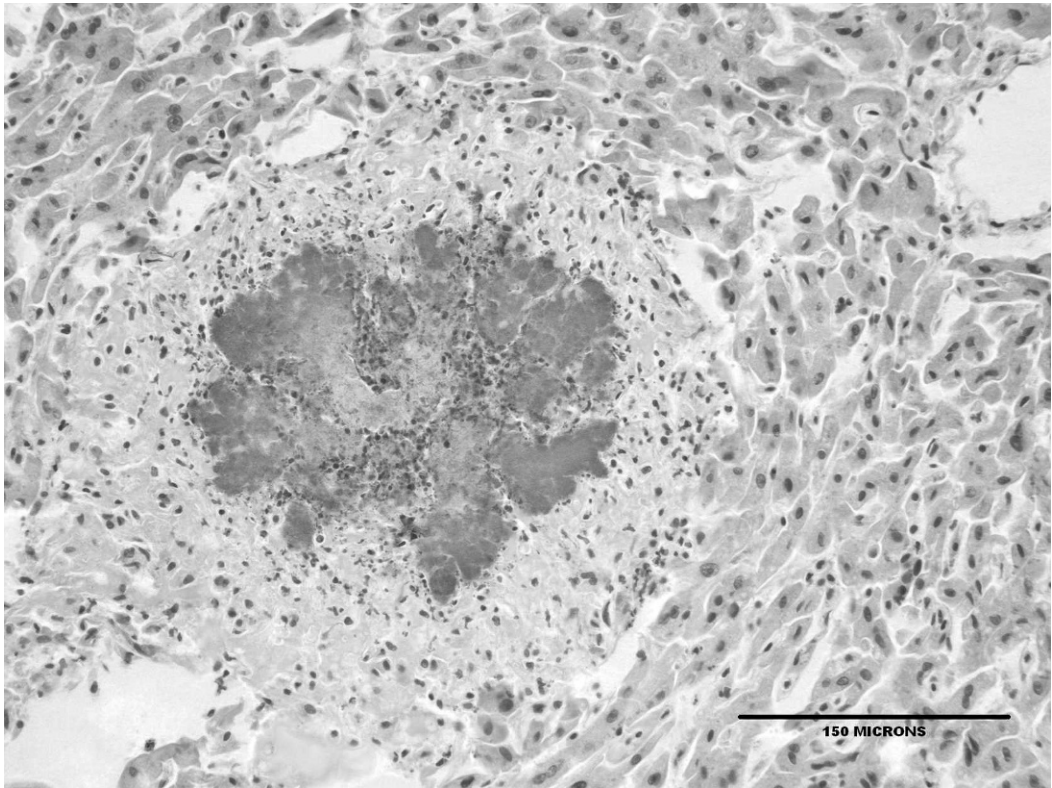


FIGURE 1. Focal necrotizing hepatitis with a lobulated colony of predominantly extracellular coccobacilli bound by a margin of inflammatory infiltrate.

bacilli (Figs. 1 and 2). Intravascular septic emboli were identified in lung, small intestine, and kidney, and discrete ulcers with scattered superficial extracellular accumulation of coccobacilli were noted on tail margins and plantar surfaces of the hind feet. Close examination of the skin did not reveal any discernible viral inclusions, and bacteria embolism to the superficial dermis and subsequent infarction of the overlying tissues was considered a possible cause of these lesions. No significant lesions were apparent within the adipose tissue, colon, duodenum, epididymis, peripheral nerves, skeletal muscle, testes, thyroid gland, thymus, or urinary bladder.

Polymerase chain reaction performed on liver and lung failed to amplify nucleic acid of the bacterium *Francisella tularensis* using techniques previously described (Ver-

sage et al., 2003). Aerobic bacterial culture was performed on Columbia blood agar, incubated at $35\text{ C} \pm 2\text{ C}$ in 5–10% CO_2 , and on MacConkey agar, at $35\text{ C} \pm 2\text{ C}$ in O_2 , for 18–24 hr. Culture yielded heavy growth of *Yersinia pseudotuberculosis* from the lung, liver, and spleen. Suspect colonies were subcultured to purity plates of Columbia blood agar; initial identification included observation of colony morphology (small, grayish, shiny, nonhemolytic on Columbia blood agar; small, nonlactose fermenter on MacConkey), gram stain (gram-negative coccobacillus), catalase (positive), oxidase (negative), indole (negative), and tube urea (positive). Confirmation of *Yersinia pseudotuberculosis* identification was made using the API 20E (bioMérieux, Marcy-l'Étoile, France). Specifically, colonies of suspect *Yersinia pseudotuberculosis* were inoculated to an API 20E strip

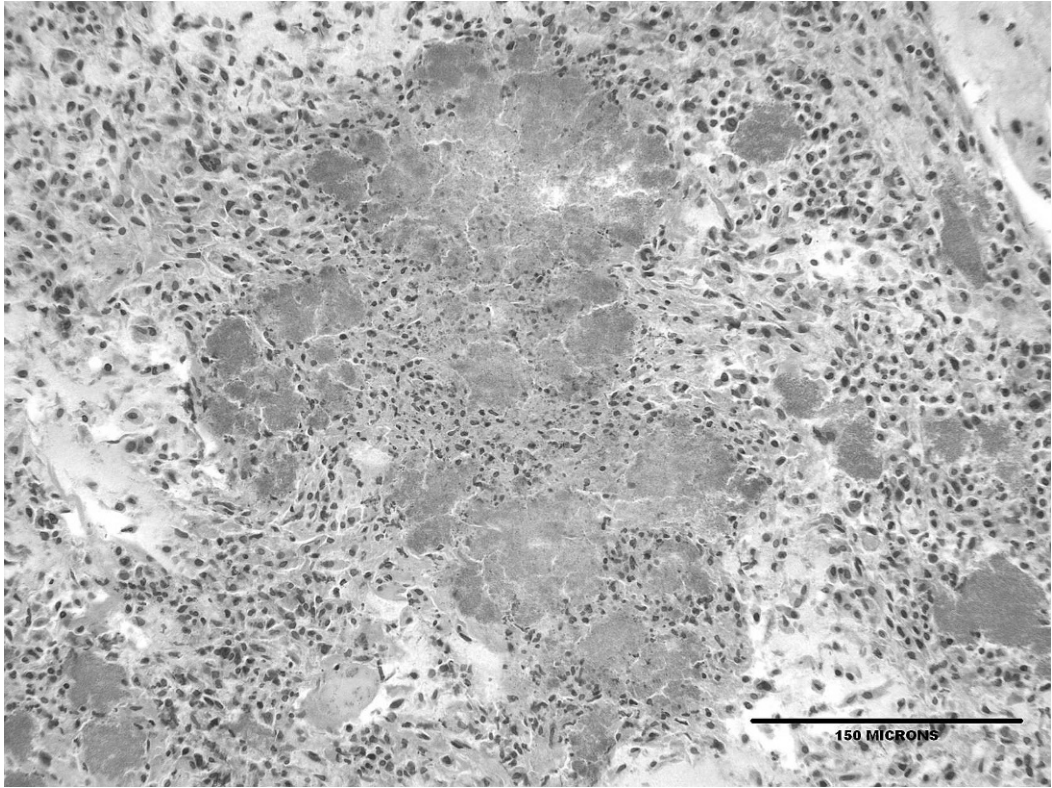


FIGURE 2. Multifocal to coalescing and necrotizing splenitis with numerous intralésional bacteria.

according to the manufacturer's instructions and incubated at $35\text{ C} \pm 2\text{ C}$ for 18–24 hr. The resulting API 20E profile (1–0–1–4–1–1–2) gave a 99.8% match to *Yersinia pseudotuberculosis*. The organism was nonmotile at $35\text{ C} \pm 2\text{ C}$, ornithine negative, VP negative, citrate negative, indole negative, urea positive, sorbitol negative, rhamnose positive, sucrose negative, and melibiose negative. Confirmation of *Y. pseudotuberculosis* identification is not usually required by the Animal Health Centre (Abbotsford, British Columbia, Canada), and the isolate was not sent to an outside laboratory for confirmation, serotyping, or biotyping. Unfortunately, the isolate was not retained, preventing later identification of specific biotype and serotype. Later attempts to amplify nucleic acid from paraffin-embedded tissue were unsuccessful. Hubbert et al. (1972), however, reported prior identification of

serotypes IA, IB, IIB, and III from Washington, USA.

Yersinia pseudotuberculosis has been reported from beavers from Ontario, Canada; (Hacking and Sileo, 1974), Minnesota, USA; Montana, USA; Washington, USA; and Wyoming, USA (Hubbert et al., 1972). Of these cases, complete necropsy results are only reported from one animal where gross and microscopic liver and spleen lesions were observed (Hacking and Sileo, 1974). This beaver from San Juan Island, USA, had not only similar hepatic and splenic lesions but also multiple systemic lesions suggestive of acute septicemia and subsequent multi-systemic intravascular septic emboli. In this beaver, infection with *Y. pseudotuberculosis* did not cause microabscesses in the lamina propria of the small intestine with lymphadenitis that is typically seen histologically in other mammalian wildlife,

such as farmed cervids (Sanford, 1995), muskoxen (*Ovibus moschatus*; Blake et al., 1991), gray fox (*Urocyon cinereoargenteus*; Black et al., 1996), and raccoons (*Procyon lotor*; Hacking and Sileo, 1974). Although one case does not give a complete picture of the pathogenesis of a disease in a species, findings from this case on San Juan Island, USA, suggest that beavers can be acutely impacted by infection, developing septicemia subsequent to rapid spread of the bacterium from the gastrointestinal tract.

The number of medium to large species of wild terrestrial mammals on the 142.6 km² San Juan Island, USA, is limited. Although population density estimates are not available, sighting frequency supports that black-tailed deer (*Odocoileus hemionus columbianus*), European rabbits (*Oryctolagus cuniculus*), mink (*Mustela vison*), raccoons, red foxes (*Vulpes vulpes*), and river otters (*Lontra canadensis*) occur at much higher densities than do beaver and muskrat (*Ondatra zibethicus*). Despite other mammals, including aquatic ones like mink and river otter, occurring at higher densities, *Y. pseudotuberculosis*-associated mortality was only reported in a beaver via the island's informal wildlife mortality surveillance system that locates and reports injured and dead wildlife.

Multiple historical reports of *Y. pseudotuberculosis*-associated mortality in beavers from other locations, pathology results from this case, suggesting an acute infection leading to mortality and an apparent predilection for causing mortality in this species more frequently than in other sympatric species, imply that, in areas where they occur in North America, beavers could be good sentinels for the regional occurrence of *Y. pseudotuberculosis*.

Although the epidemiology of *Y. pseudotuberculosis* is not completely understood, it is believed that wild birds (Hamasaki et al., 1989; Niskanen et al., 2002) and some wild rodents (Hubbert,

1972; Fukushima and Gomyoda, 1991) can be asymptomatic carriers or reservoirs of the bacterium. Humans are exposed to *Y. pseudotuberculosis* through ingestion of contaminated drinking water (Fukushima et al., 1988), meat, or milk (Hubbert et al., 1972) or exposure to infected animals or contaminated soils (Gasper and Watson, 2001). *Yersinia pseudotuberculosis* mortality in beavers should serve as a public warning to increase efforts to control peridomestic rodent populations and to better protect food and water supplies from fecal contamination by rodents and birds.

We thank the staff at Wolf Hollow Wildlife Rehabilitation Center for collecting and submitting this case, A. Traxler and the volunteers from the Whale Museum and the San Juan County Marine Mammal Stranding Network for assisting with the gross necropsy, and two anonymous reviewers for comments that strengthened the manuscript. Encouragement and permission to submit tissues to the Abbotsford, BC, Canada, diagnostic laboratory was given by K. Mansfield, of the Washington Department of Fish and Wildlife, and D. McAloose and A. Newton provided assistance with photomicrographs.

LITERATURE CITED

- ACHTMAN, M., K. ZURTH, G. MORELLI, G. TORREA, A. GUIYOULE, AND E. CARNIEL. 1999. *Yersinia pestis*, the cause of plague, is a recently emerged clone of *Yersinia pseudotuberculosis*. *Proceedings of the National Academy of Sciences* 96: 14043–14048.
- BLACK, S. S., F. W. AUSTIN, AND E. MCKINLEY. 1996. Isolation of *Yersinia pseudotuberculosis* and *Listeria monocytogenes* serotype 4 from a gray fox (*Urocyon cinereoargenteus*) with canine distemper. *Journal of Wildlife Diseases* 32: 362–366.
- BLAKE, J. E., B. D. MCLEAN, AND A. GUNN. 1991. Yersiniosis in free-ranging musk oxen on Banks Island, Northwest Territories, Canada. *Journal of Wildlife Diseases* 27: 527–533.
- FUKUSHIMA, H., AND M. GOMYODA. 1991. Intestinal carriage of *Yersinia pseudotuberculosis* by wild birds and mammals in Japan. *Applied Environmental Microbiology* 57: 1152–1155.
- , ———, K. SHIOZAWA, S. KANEKO, AND M. TSUBOKURA. 1988. *Yersinia pseudotuberculosis*

- infection contracted through water contaminated by a wild animal. *Journal of Clinical Microbiology* 26: 584–585.
- GASPER, P. W., AND R. P. WATSON. 2001. Plague and yersiniosis. In *Infectious diseases of wild mammals*, E. S. Williams and I. K. Barker (eds.). Iowa State University Press, Ames, Iowa, pp. 313–329.
- HACKING, M. A., AND L. SILEO. 1974. *Yersinia enterocolitica* and *Yersinia pseudotuberculosis* from wildlife in Ontario. *Journal of Wildlife Diseases* 10: 452–456.
- HAMASAKI, S., H. HAYASHIDANI, K. KANEKO, M. OGAWA, AND Y. SHIGETA. 1989. A survey for *Yersinia pseudotuberculosis* in migratory birds in coastal Japan. *Journal of Wildlife Diseases* 25: 401–403.
- HUBBERT, W. T. 1972. Yersiniosis in mammals and birds in the United States. *American Journal of Tropical Medicine and Hygiene* 21: 458–463.
- LARSON, J. S. 1967. Age structure and sexual maturity within a western Maryland beaver (*Castor canadensis*) population. *Journal of Mammalogy* 48: 408–413.
- NISKANEN, T., J. WALDENSTROM, M. FREDRIKSSON-AHOMAA, B. OLSEN, AND H. KORKEALA. 2002. *virF*-Positive *Yersinia pseudotuberculosis* and *Yersinia enterocolitica* found in migratory birds in Sweden. *Applied and Environmental Microbiology* 69: 4670–4675.
- SANFORD, S. E. 1995. Outbreaks of yersiniosis caused by *Yersinia pseudotuberculosis* in farmed cervids. *Journal of Veterinary Diagnostic Investigation* 7: 78–81.
- SATO, K., AND M. KOMAGANE. 1991. *Yersinia pseudotuberculosis* infection in children due to untreated drinking water. *Contributions to Microbiology and Immunology* 12: 5–10.
- WALLNER-PENDLETON, E., AND G. COOPER. 1983. Several outbreaks of *Yersinia pseudotuberculosis* in California turkey flocks. *Avian Diseases* 27: 524–526.
- VERSAGE, J. L., D. SEVERIN, M. CHU, AND J. PETERSON. 2003. Development of a Multitargeted Real-Time TaqMan PCR assay for the enhanced detection of *Francisella tularensis* in complex specimens. *Journal of Clinical Microbiology* 41: 5492–5499.

Received for publication 20 October 2008.