

Pathology and Epidemiology of Phocid Herpesvirus-1 in Wild and Rehabilitating Harbor Seals (*Phoca vitulina richardsi*) in the Northeastern Pacific

C. G. Himworth,^{1,8} M. Haulena,² D. M. Lambourn,³ J. K. Gaydos,⁴ J. Huggins,⁵ J. Calambokidis,⁵ J. K. B. Ford,⁶ K. Zaremba,² and S. Raverty⁷ ¹ Department of Veterinary Pathology, University of Saskatchewan, 52 Campus Dr., Saskatoon, Saskatchewan S7N 5B4, Canada; ² Vancouver Aquarium, PO Box 3232, Vancouver, British Columbia V6B 3X8, Canada; ³ Washington Department of Fish and Wildlife, Marine Mammal Investigations, 7801 Phillips Rd. SW, Lakewood, Washington 98498, USA; ⁴ Wildlife Health Center—Orcas Island Office, University of California Davis School of Veterinary Medicine, 942 Deer Harbor Rd., Eastsound, Washington 98245, USA; ⁵ Cascadia Research, 218 1/2 W 4th Ave., Olympia, Washington 98501, USA; ⁶ Pacific Biological Station, Fisheries and Oceans Canada, 3190 Hammond Bay Road, Nanaimo, British Columbia V9T 6N7, Canada; ⁷ Animal Health Centre, 1767 Angus Campbell Rd., Abbotsford, British Columbia V3G 2M3, Canada; ⁸ Corresponding author (email: chelsea.himworth@usask.ca)

ABSTRACT: Phocid herpesvirus-1 (PhHV-1, subfamily Alphaherpesvirinae) was isolated from harbor seals (*Phoca vitulina vitulina*) in the Netherlands in 1985, and was subsequently identified in Pacific harbor seals (*Phoca vitulina richardsi*) from California, USA in the 1990s. PhHV-1-associated pathology was first recognized in harbor seal carcasses submitted to a veterinary diagnostic laboratory in Abbotsford, British Columbia, Canada in 2000, and 63 cases were identified by 2008. A review of these cases indicated that PhHV-1-associated disease is widespread in harbor seals in the wild and within rehabilitation facilities in the coastal northeastern Pacific (including British Columbia, Canada, and Washington, USA). Morbidity and mortality occurred primarily in neonatal and weanling seal pups, and was due to PhHV-1 alone, or in combination with other disease processes. All cases occurred between July and October, corresponding to the pupping and weaning seasons in this area. Although previous publications have described the prevalence of antibody to PhHV-1 in harbor seals from British Columbia, Canada and Washington, USA this is the first study to focus on the epidemiology and pathology of the virus in this region.

Key words: Harbor seal, northeastern Pacific, *Phoca vitulina*, phocid herpesvirus-1.

Phocid herpesvirus-1 (PhHV-1), subfamily Alphaherpesvirinae, was first isolated in 1985 from harbor seals (*Phoca vitulina vitulina*) in the Netherlands (Osterhaus et al., 1985), and was identified in Pacific harbor seals (*Phoca vitulina richardsi*) from California, USA in the

early 1990s (Gulland et al., 1997). In the Pacific Ocean, PhHV-1-associated lesions have included adrenal and hepatic necrosis with intranuclear viral inclusions and, occasionally, nonsuppurative meningoencephalitis (Gulland et al., 1997). In contrast, lesions in harbor seals from the Atlantic Ocean have consisted of interstitial pneumonia and hepatic necrosis (Osterhaus et al., 1985; Borst et al., 1986). Phocid herpesvirus-1 appears to be endemic in Pacific harbor seal populations (Goldstein et al., 2003) and disease is most common in young pups, both free ranging and in rehabilitation facilities (Gulland et al., 1997; King et al., 2001; Goldstein et al., 2004).

Other than serologic investigations (Goldstein et al., 2003), comprehensive reports of PhHV-1 infection in the Pacific have been limited to seals in California, USA (Gulland et al., 1997; King et al., 2001; Goldstein et al., 2004, 2005). The objective of this study was to describe retrospectively the epidemiology and pathology associated with PhHV-1 in the northeastern Pacific (British Columbia [BC], Canada, and Washington, USA) through a review of harbor seal cases submitted to a regional veterinary diagnostic laboratory.

Pathology reports for all harbor seal carcasses submitted to the Animal Health

Centre (AHC), Abbotsford, BC, Canada from January 2000 to December 2008 were reviewed. Submitted harbor seals were found dead in the wild or died while at one of three rehabilitation facilities (two in BC, Canada and one in Washington, USA). Complete necropsies were performed and multiple tissues, including adrenal gland, liver, lung, heart, kidney, brain, spleen, stomach, pancreas, intestine, lymph node, skeletal muscle, and any tissue with observed gross pathology were collected and fixed in 10% neutral-buffered formalin. Formalin-fixed tissues were processed routinely, embedded in paraffin, sectioned at 5 μm , and stained with hematoxylin and eosin (HE) for microscopic examination. Fresh tissues, including lung, brain, spleen, and small intestine, were collected for routine aerobic culture. Where indicated, specific culture for anaerobes, *Salmonella* spp., or *Clostridium difficile* was performed. When available, presubmission records regarding geographic origin or site of stranding and date of death or recovery of beach-cast carcasses were reviewed.

For purposes of this study, a seal was considered to have PhHV-1-related disease if there was adrenal or hepatic necrosis with discernible intranuclear inclusion bodies in one or both of these tissues (Gulland et al., 1997). Seals that met these criteria are herein referred to as PhHV-1 positive. Because the incubation time for PhHV-1 is thought to be ≥ 10 days (Kennedy-Stoskopf, 2001), any animal with PhHV-1-associated lesions that had been in a rehabilitation facility ≤ 10 days was considered to have been infected in the wild. Animals that had been in a rehabilitation center > 10 days could have been infected in the wild or within the rehabilitation facility.

Despite comprehensive and systematic necropsies of harbor seal carcasses throughout the 1990s, PhHV-1 infection was first detected in 2000, with a total of 63 PhHV-1-positive seals identified by 2008 (Fig. 1). Of the 61 PhHV-1-positive

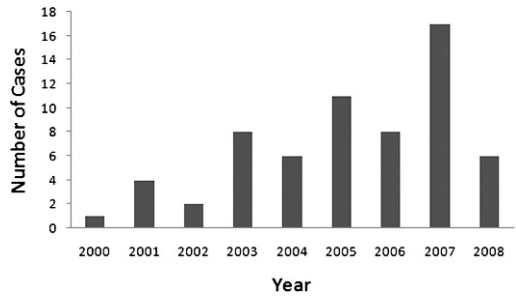


FIGURE 1. Number of harbor seal carcasses from the northeastern Pacific with PHV-1-associated disease submitted to a veterinary diagnostic laboratory between 2000 and 2008.

seals for which date of mortality was known, 7 (11%) died in July, 37 (61%) died in August, 16 (26%) died in September, and 1 (2%) died in October. Cases originated widely throughout the inland waters of Washington, USA and BC, Canada, with fewer coming from the outer coast of Vancouver Island, Canada (Fig. 2). However, variability in surveillance for beach-cast and dead seals among areas of the northeastern Pacific coast may affect apparent geographic distribution of cases.

Of the 53 PhHV-1-positive animals for which data on age and sex were available, 46 (87%) were neonates (determined by presence of an umbilicus and/or lanugo coat, incomplete tooth eruption, and a body weight of < 25 kg) and 7 (13%) were weanlings (determined by time of year, complete tooth eruption, little or no umbilical remnant, and a body weight of < 35 kg) (Cottrell et al., 2002; Ronald and Gotts, 2003). Twenty-seven (51%) were females and 26 (49%) were males.

Presubmission records were available for 44 animals; 12 (27%) were found dead in the wild, and 32 (73%) spent some time in a rehabilitation facility prior to death. There was no significant difference in age ($P=0.26$) or sex ($P=0.56$) distribution between PhHV-1-positive animals found dead on the wild and those that died at a rehabilitation facility (chi-square test, STATA/IC 10.0, StatCorp Lp, College

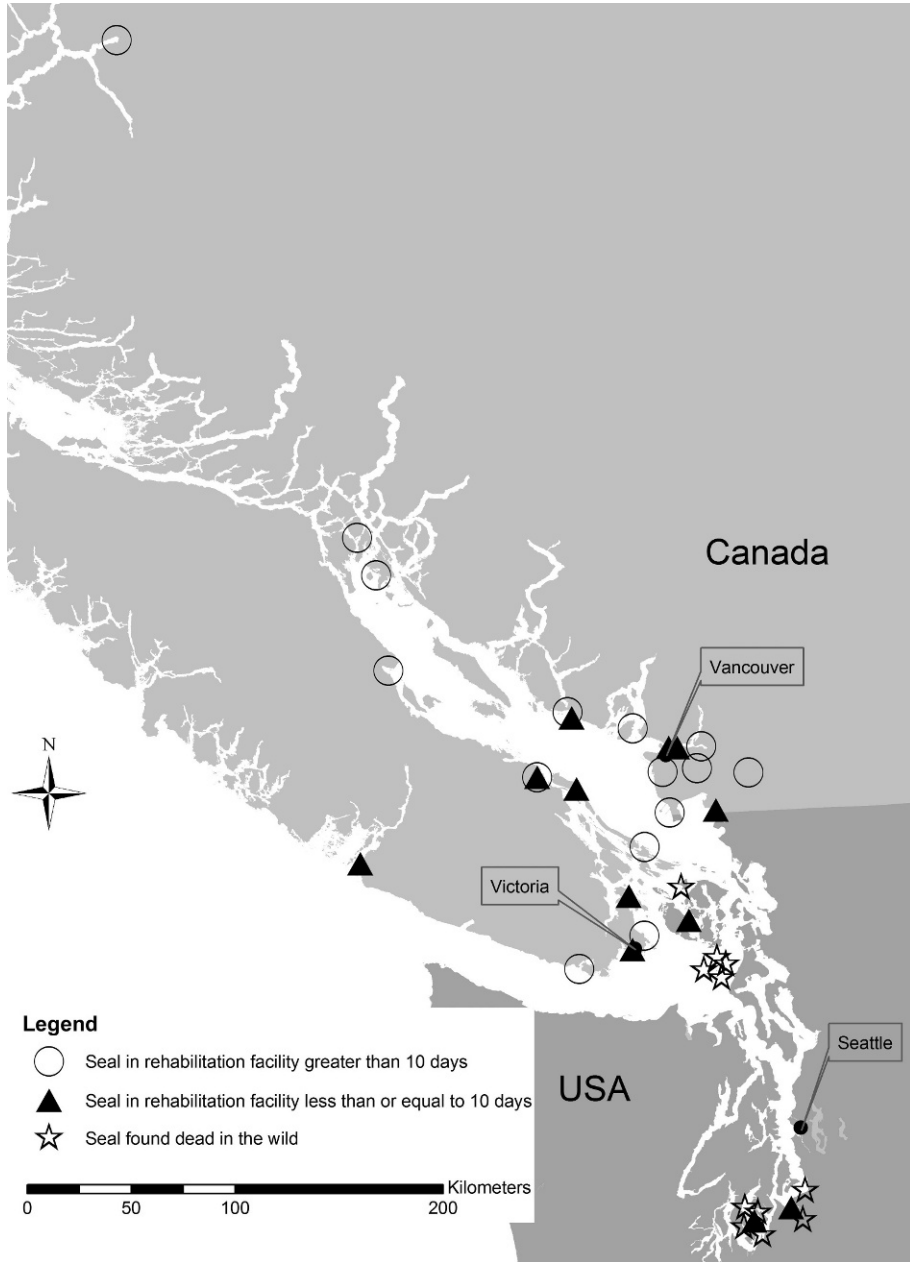


FIGURE 2. Map of southwest British Columbia, Canada, and northwest Washington, USA, illustrating the geographic origin of PHV-1-positive, beach-caste harbor seal carcasses and live, stranded seals distinguished by duration of time spent in a rehabilitation facility.

Station, Texas, USA, at an alpha level of 0.05).

Time spent in rehabilitation prior to death was available for 31 of 32 seals that died in rehabilitation centers and ranged from 1 to 45 days. Of these 31 seals, 12

(39%) were in rehabilitation for <10 days prior to death and were therefore considered to have been infected in the wild (Fig. 2), 5 (16%) were in rehabilitation for 10 days to 2 wk, 6 (19%) for 2–3 wk, 2 (6%) for 3–4 wk, and 6 (19%) for >1 mo.

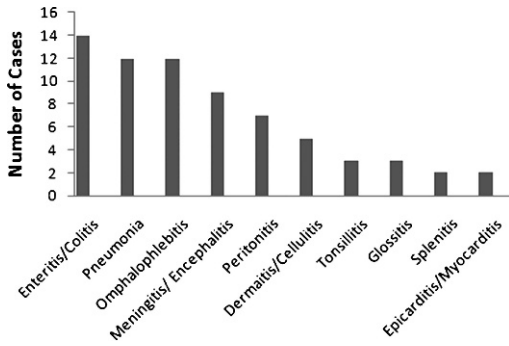


FIGURE 3. Summary of preexisting or supervening pathology observed in PhHV-1-positive harbor seal carcasses submitted to a veterinary diagnostic laboratory. Seals with more than one lesion are represented multiple times.

Of the 63 PhHV-1-positive seals, 60 (95%) had adrenal necrosis, which included intranuclear viral inclusions in 57 (90%) cases and 26 (41%) had hepatic necrosis, with intranuclear viral inclusions in 14 (22%) cases. Two (3%) animals had nonsuppurative encephalitis and 4 (6%) had interstitial pneumonia in association with pathology typical of PhHV-1 infection (i.e., adrenal and hepatic necrosis) in the absence of other disease. These lesions may therefore have been caused by PhHV-1 (Borst et al., 1986; Gulland et al., 1997).

Twenty of 63 seals (32%) had lesions attributable only to PhHV-1 infection. Presubmission records were available for 10 of these 20, all of which were part of the cohort of 32 animals that had spent time in a rehabilitation center prior to death. For the remaining 43 (68%) seals, in addition to PhHV-1 infection, pathology associated with other, unrelated disease processes was observed (Fig. 3). The most common nonPhHV-1-related lesions included enteritis/colitis, omphalophlebitis, pneumonia, and dermatitis/cellulitis.

Bacteriology results were available for 55 of 63 seals, of which 39 (71%) yielded growth on culture (Fig. 4). Isolates recovered were similar to those previously reported in harbor seals that succumb to conditions other than fulminant PhHV-1 infection (Steiger et al., 1989; Lockwood et al., 2006), although some may have been the result of postmortem overgrowth.

In this study, all PhHV-1-positive seals were neonates or weanlings, which is consistent with previous reports (Gulland et al., 1997; Goldstein et al., 2005). There was marked temporal clustering of cases, all of which occurred between July and October (with peak submissions in August). Although observer bias related to increased surveillance of seal haulout sites

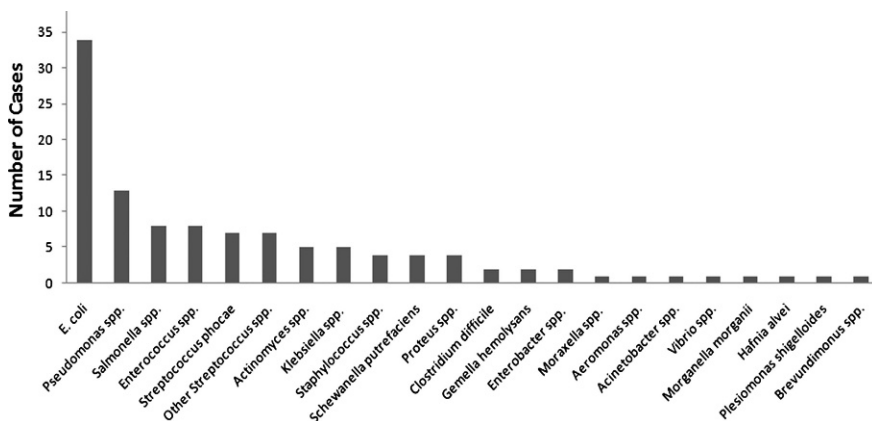


FIGURE 4. Summary of bacterial species isolated from PHV-1-positive harbor seal carcasses submitted to a veterinary diagnostic laboratory. Seals in which more than one species was isolated are represented multiple times.

in the summer and fall may partially explain this result, it is more likely a reflection of the harbor seal pupping season in BC, Canada and Washington, USA, which takes place between June and September and is followed by weaning and breeding 4–6 wk later (Cottrell et al., 2002; Ronald and Gotts, 2003). During this period the greatest number of PhHV-1-susceptible seals (i.e., young of the year) are present within the population and adults are likely to be shedding virus, leading to increased PhHV-1 transmission and disease (Gulland et al., 1997; King et al., 2001). Rehabilitation centers receive large numbers of seal pups at this time of year (Himsworth, unpubl.), which can result in the introduction and subsequent transmission of the virus within these facilities. Cases of PhHV-1-associated disease in BC, Canada and Washington, USA appeared to occur later in the year than in California, USA, which is likely a result of geographic variation in the harbor seal pupping season (Gulland et al., 1997; King et al., 2001; Cottrell et al., 2002; Ronald and Gotts, 2003; Goldstein et al., 2004).

Mortality can occur as a result of PhHV-1 infection alone (Gulland et al., 1997), as was observed in this study. However, similar to previously reports (Gulland et al., 1997; King et al., 2001; Goldstein et al., 2005), the majority of PhHV-1-infected animals presented with other preexisting or supervening disease processes. In these cases, it is difficult to determine the role of PhHV-1 in seal morbidity and mortality, as PhHV-1 could predispose a pup to secondary infections and other diseases that may increase the pathogenicity of PhHV-1. Additionally, young seals may be immunocompromised for other reasons, including malnutrition and waning maternal immunity, and thus be more prone to opportunistic infections.

In BC, Canada and Washington, USA, as in California, USA, PhHV-1 appears to be enzootic in free-ranging seal populations, with transmission also occurring in rehabilitation centers, presumably subse-

quent to admission of PhHV-1-infected wild harbor seals (Gulland et al., 1997; King et al., 2001; Goldstein et al., 2004). In this study, all seals that appeared to suffer mortality due to PhHV-1 infection alone had spent some time in a rehabilitation facility prior to death. Outbreaks of PhHV-1-associated disease and mortality have been observed in rehabilitation facilities on the Atlantic and Pacific coasts (Borst et al., 1986; Gulland et al., 1997; King et al., 2001). The increased incidence and severity of PhHV-1-related disease in these facilities is likely a consequence of some combination of crowding, physiologic compromise, waning maternal immunity, and psychologic stress associated with human intervention.

Overall, it appears that the epidemiology and pathology associated with PhHV-1 in the northeastern Pacific is most similar to that reported in California, USA. Infection is likely widespread in harbor seal populations throughout the coasts of BC, Canada and Washington, USA, with morbidity and mortality occurring primarily in young seals and due to PhHV-1 alone or in concert with other disease processes.

We thank the staffs of the marine mammal stranding network and harbor seal rehabilitation centers, specifically the Wolf Hollow Wildlife Rehabilitation Center, the Vancouver Aquarium, the San Juan County Marine Mammal Stranding Network, and the Whale Museum, who helped with this work. Funding and support for this work was provided by the Washington Department of Fish and Wildlife, Cascadia Research, SeaDoc Society, the John H. Prescott Marine Mammal Rescue Assistance Grant Program, and the Western College of Veterinary Medicine Interprovincial Graduate Fellowship. Portions of this work were authorized under the U.S. Marine Mammal Protection Act by Scientific Research 782-1702.

LITERATURE CITED

- BORST, G. H., H. C. WALVOORT, P. J. REIJNDERS, J. S. VAN DER KAMP, AND A. D. OSTERHAUS. 1986. An

- outbreak of a herpesvirus infection in harbor seals (*Phoca vitulina*). *Journal of Wildlife Diseases* 22: 1–6.
- COTTRELL, P. E., S. JEFFRIES, B. BECK, AND P. S. ROSS. 2002. Growth and development in free-ranging harbor seal (*Phoca vitulina*) pups from southern British Columbia, Canada. *Marine Mammal Science* 18: 721–733.
- GOLDSTEIN, T., F. M. GULLAND, B. M. ALDRIDGE, J. T. HARVEY, T. ROWLES, D. M. LAMBOURN, S. J. JEFFRIES, L. MEASURES, P. J. YOCHER, B. S. STEWART, R. J. SMALL, D. P. KING, J. L. STOTT, AND J. A. MAZET. 2003. Antibodies to phocine herpesvirus-1 are common in North American harbor seals (*Phoca vitulina*). *Journal of Wildlife Diseases* 39: 487–494.
- , J. A. MAZET, F. M. GULLAND, T. ROWLES, J. T. HARVEY, S. ALLEN, D. P. KING, B. M. ALDRIDGE, AND J. L. STOTT. 2004. The transmission of phocine herpesvirus-1 in rehabilitating and free-ranging Pacific harbor seals (*Phoca vitulina*) in California. *Veterinary Microbiology* 103: 131–141.
- , ———, L. J. LOWENSTINE, F. M. GULLAND, T. K. ROWLES, D. P. KING, AND B. M. ALDRIDGE. 2005. Tissue distribution of phocine herpesvirus-1 (PhHV-1) in infected harbour seals (*Phoca vitulina*) from the central Californian coast and a comparison of diagnostic methods. *Journal of Comparative Pathology* 133: 175–183.
- GULLAND, F. M., L. J. LOWENSTINE, J. M. LAPOINTE, T. SPRAKER, AND D. P. KING. 1997. Herpesvirus infection in stranded Pacific harbor seals of coastal California. *Journal of Wildlife Diseases* 33: 450–458.
- KENNEDY-STOSKOFF, S. 2001. Viral diseases. In *CRC handbook of marine mammal medicine*, L. A. Dierauf and M. D. Gulland (eds.). 2nd Edition. CRC Press, Boca Raton, Florida, pp. 285–303.
- KING, D. P., A. R. LIE, T. GOLDSTEIN, B. M. ALDRIDGE, F. M. GULLAND, M. HAULENA, M. A. ADKISON, L. J. LOWENSTINE, AND J. L. STOTT. 2001. Humoral immune responses to phocine herpesvirus-1 in Pacific harbor seals (*Phoca vitulina richardsii*) during an outbreak of clinical disease. *Veterinary Microbiology* 80: 1–8.
- LOCKWOOD, S. K., J. L. CHOVAN, AND J. K. GAYDOS. 2006. Aerobic bacterial isolations from harbor seals (*Phoca vitulina*) stranded in Washington: 1992–2003. *Journal of Zoo and Wildlife Medicine* 37: 281–291.
- OSTERHAUS, A. D., H. YANG, H. E. SPIJKERS, J. GROEN, J. S. TEPPEMA, AND S. G. VAN. 1985. The isolation and partial characterization of a highly pathogenic herpesvirus from the harbor seal (*Phoca vitulina*). *Archives of Virology* 86: 239–251.
- RONALD, K., AND B. L. GOTTS. 2003. Seals. In *Wild mammals of North America*, G. A. Feldhammer, B. C. Thompson, and J. A. Chapman (eds.). 2nd Edition. Johns Hopkins University Press, Baltimore, Maryland, pp. 789–854.
- STEIGER, G. H., J. CALAMBOKIDIS, J. C. CUBBAGE, D. E. SKILLING, A. W. SMITH, AND D. H. GRIBBLE. 1989. Mortality of harbor seal pups at different sites in the inland waters of Washington. *Journal of Wildlife Diseases* 25: 319–328.

Submitted for publication 20 June 2009.

Accepted 17 August 2009.